

Use of intravenous immunoglobulin in a patient with refractory myasthenia gravis associated with malignant thymoma

KK Lau, WC Ho

We report on a case of refractory myasthenia gravis that was managed by using intravenous immunoglobulin. A 35-year-old Chinese woman with malignant thymoma-associated myasthenia gravis was treated by total thymectomy, followed by chemotherapy. Thirty months later, she developed respiratory failure and required mechanical ventilation for 2 months. A course of intravenous immunoglobulin was given and her condition improved significantly. Two weeks later, the patient became ambulatory, was prescribed oral pyridostigmine, and was discharged home.

HKMJ 1999;5:291-3

Key words: Immunoglobulins, intravenous/therapeutic use; Myasthenia gravis/therapy; Thymoma/surgery

Introduction

Intramuscular immunoglobulin has been used for many years to passively protect non-immune individuals from infectious diseases. Since 1981, intravenous immunoglobulin (IVIG) preparations have been used with clinical efficacy in a number of diseases, including idiopathic thrombocytopenic purpura, Kawasaki syndrome, Guillain-Barré syndrome, and chronic inflammatory demyelinating polyneuropathies. However, the clinical efficacy of IVIG is not as well established in the treatment of myasthenia gravis. Until now, there have been only individual case reports of its efficacy in treating myasthenia gravis.^{1,2} This article describes the usefulness of IVIG treatment in a patient who had refractory myasthenia gravis associated with malignant thymoma.

Case report

A 35-year-old Chinese woman presented to the Department of Medicine at the Princess Margaret Hospital in December 1994 with a 6-month history of dysarthria, dysphagia, and weakness of all four limbs. Her body weight had decreased by 8 kg during this period. There

was no history of any other significant medical illness. The results from a barium meal test were normal. Physical examination did not reveal any skin lesion, enlarged lymph nodes, or breathing abnormality. The main finding was easy fatigability. The patient could only maintain her upper limbs in an extended posture for 45 seconds (normal duration for healthy adults, >4 minutes). However, there was neither muscle wasting nor myalgia, and all the tendon reflexes were normal and symmetrical. After receiving edrophonium chloride 10 mg intravenously (the Tensilon test), the patient could keep her upper limbs in extended position for 2 minutes 15 seconds. The chest X-ray showed a mediastinal mass and computerised tomography (CT) of the thorax showed an anterior mediastinal mass of 6 x 4 x 7 cm. The paraspinal lymph nodes were not enlarged and there was no pleural effusion. A nerve conduction study was performed and repetitive muscle stimulation resulted in a gradual decrement in the compound muscle action potential (CMAP). Over the right trapezius muscle, the fourth CMAP was only 54% of the first CMAP when the frequency of stimulation was 3 Hz. Anti-acetylcholine receptor (AChR) and anti-striated muscle antibodies were present. The diagnosis was myasthenia gravis and a thymic mass.

A total thymectomy was performed. Pleural seedings were noted in the left pleural cavity, and the disease was consequently classified as staged IVa. Histological study showed a well-differentiated thymic carcinoma (using the Müller-Hermelink classification) [Fig]. Postoperatively, chemotherapy was prescribed—

Princess Margaret Hospital, Princess Margaret Hospital Road,
Kwai Chung, Hong Kong
Department of Medicine
KK Lau, MRCP, FHKAM (Medicine)
Department of Pathology
WC Ho, FRCPA, FHKCP

Correspondence to: Dr KK Lau

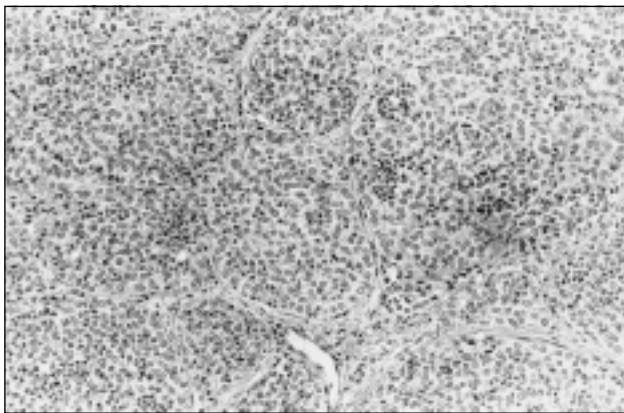


Fig. Photomicrograph of well-differentiated thymic carcinoma showing a predominance of irregular epithelial cells and scanty lymphoid cells (H&E, x70)

namely, vincristine sulphate, cyclophosphamide, adriamycin, and cisplatin. Alopecia developed and the patient was given a blood transfusion to treat anaemia. Nineteen months later, there was an enlarged left supraclavicular lymph node. The results of a culture of an aspirated sample revealed an infection with *Mycobacterium tuberculosis*, for which antituberculous drugs were given according to the bacterial sensitivity; no aminoglycoside was given. Eleven months after the initiation of antituberculous therapy, respiratory failure developed and the patient required mechanical ventilation as well as intensive care support for 2 months. She had signs and symptoms of pyridostigmine overdose when this drug was given at 80 mg five times per day. However, when pyridostigmine was given at a dose of less than 80 mg five times per day, there were signs and symptoms of weakness and fatiguability, and a continued dependence on mechanical ventilation. Other causes for weakness, such as the prescription of particular drugs, infection, myositis, electrolyte imbalance, trace element deficiency, and endocrinopathy were excluded.

A course of IVIG 0.4 g·kg⁻¹·d⁻¹ was given for 5 days and proved to be effective. The patient's motor power gradually improved. She could breathe unassisted on day 3 and there was further improvement at the end of the course of IVIG. Two weeks later, she could walk independently and was subsequently discharged home with a prescription of oral pyridostigmine 70 mg five times per day. She continued to visit the out-patient clinic at the Princess Margaret Hospital once every 8 weeks, and her condition remained stable clinically. She was last seen 6 months after discharge and given pyridostigmine 70 mg five times per day; she did not require further IVIG treatment. Anti-AchR and anti-striated muscle antibodies were found to be present. A CT scan of the thorax performed

soon after the patient was ambulatory showed metastases in the left pleural cavity, which were treated with a course of radiotherapy. The metastases could not be seen in the third CT scan of the thorax.

Discussion

Myasthenia gravis that is associated with malignant thymoma is uncommon. Two local studies of patients with myasthenia gravis showed that 4.0% to 6.3% of patients also had malignant thymoma.^{3,4} In this case report, the histological diagnosis of the malignant thymoma was well-differentiated thymic carcinoma; the left pleural metastases meant that the malignant thymoma had reached stage IVa.⁵ The 5-year survival rate reported by Wang et al⁶ was 37%. Owing to advancements in chemotherapy, the response rate has increased to between 47% and 91%.^{7,8} As the survival time has increased, the control of myasthenia gravis has become more important. In this case, after 30 months, the patient was very fragile and became dependent on mechanical ventilation for 2 months.

Myasthenia gravis is associated with the production of polyclonal antibodies to the 250000-Da glycoprotein, which acts as a receptor for acetylcholine at the postneuromuscular junction. The exact mechanism of action of IVIG is unclear. One possibility is that IVIG acts by providing anti-idiotypic antibodies that react with the anti-AchR polyclonal antibodies. A review of eight studies showed that in four of them, IVIG-containing regimens decreased the level of polyclonal anti-AChR antibodies.⁹ Since the symptoms of myasthenia gravis are associated with the production of anti-AChR antibodies, a decrease in the level of antibodies would improve the clinical state. Another possible mechanism is the inhibition of the binding of activated complement to target cells; by acting as a 'complement sponge', IVIG may favour the binding of activated complement to 'bystander' IVIG instead of target cells, thus enhancing muscle endurance. The inhibition of cytokine secretion and lymphocyte proliferation might also reduce the degree of the immune response and thus improve motor function.

The IVIG given to the patient in this case was Normal Immunoglobulin (human) prepared by Commonwealth Serum Laboratory Ltd., Victoria, Australia. It was prepared by cold ethanol fractionation of large pools of human plasma that had been obtained from voluntary blood donors. The protein was not chemically or enzymatically modified and the pH of the preparation was 4.25. The use of IVIG was efficacious in the treatment of myasthenia gravis,

which has been previously reported.¹⁰ The presence of coexisting tuberculosis and malignant thymoma with metastases, and the use of chemotherapy did not seem to affect the therapeutic effect of IVIG. There are some remaining questions, however, regarding the best time to give IVIG, the optimal dosage, and the long-term efficacy and side effects of treatment. Although giving IVIG is not recommended as the sole therapy for the treatment of myasthenia gravis, it allows a reduction in the dose of corticosteroid⁹ and can be life-saving, as illustrated in this case.

References

1. Thornton CA, Griggs RC. Plasma exchange and intravenous immunoglobulin treatment of neuromuscular disease. *Ann Neurol* 1994;35:260-8.
2. Gajdos PH, Outin H, Elkharrat D, Brunel D, et al. High-dose intravenous gammaglobulin for myasthenia gravis. *Lancet* 1984;1:406-7.
3. Yu YL, Hawkins BR, Ip MS, Wong V, Woo E. Myasthenia gravis in Hong Kong Chinese. I. Epidemiology and adult disease. *Acta Neurol Scand* 1992;86:113-9.
4. Kay R, Lam S, Wong KS, Wang A, Ho J. Response to thymectomy in Chinese patients with myasthenia gravis. *J Neurol Sci* 1994;126:84-7.
5. Masaoka A, Monden Y, Nakahara K, Tanioka T. Follow-up study of thymomas with special reference to their clinical stages. *Cancer* 1981;48:2485-92.
6. Wang LS, Huang MH, Lin TS, Huang BS, Chien KY. Malignant thymoma. *Cancer* 1992;70:2443-50.
7. Fornasiero A, Daniele O, Ghiotto C, et al. Chemotherapy of invasive thymoma. *J Clin Oncol* 1990;8:1419-23.
8. Morgenthaler TI, Brown LR, Colby TV, Harper CM, Coles DT. Symposium on intrathoracic neoplasms, part IX: thymoma. *Mayo Clin Proc* 1993;68:1110-23.
9. Arsura E. Experience with intravenous immunoglobulin in myasthenia gravis. *Clin Immunol Immunopathol* 1989; 53(Suppl):170S-179S.
10. Arsura EL, Bick A, Brunner NG, Namba T, Grob D. High-dose intravenous immunoglobulin in the management of myasthenia gravis. *Arch Intern Med* 1986;146:1365-8.

Instructions for Letters to the Editor

Letters discussing a recent article in the *Hong Kong Medical Journal* are welcome. They should be received within 6 weeks of the article's publication and can be faxed to the Editorial Office at (852) 2505 5577 or e-mailed to <hkjmj@gateway.net.hk>. Original letters that do not refer to an article in the *Hong Kong Medical Journal* may also be considered.

Letters should be type-written double-spaced, should not exceed 500 words, and have no more than five references. Letters may be edited before publication. Please include telephone and fax numbers. Financial associations or other possible conflicts of interest should always be disclosed.